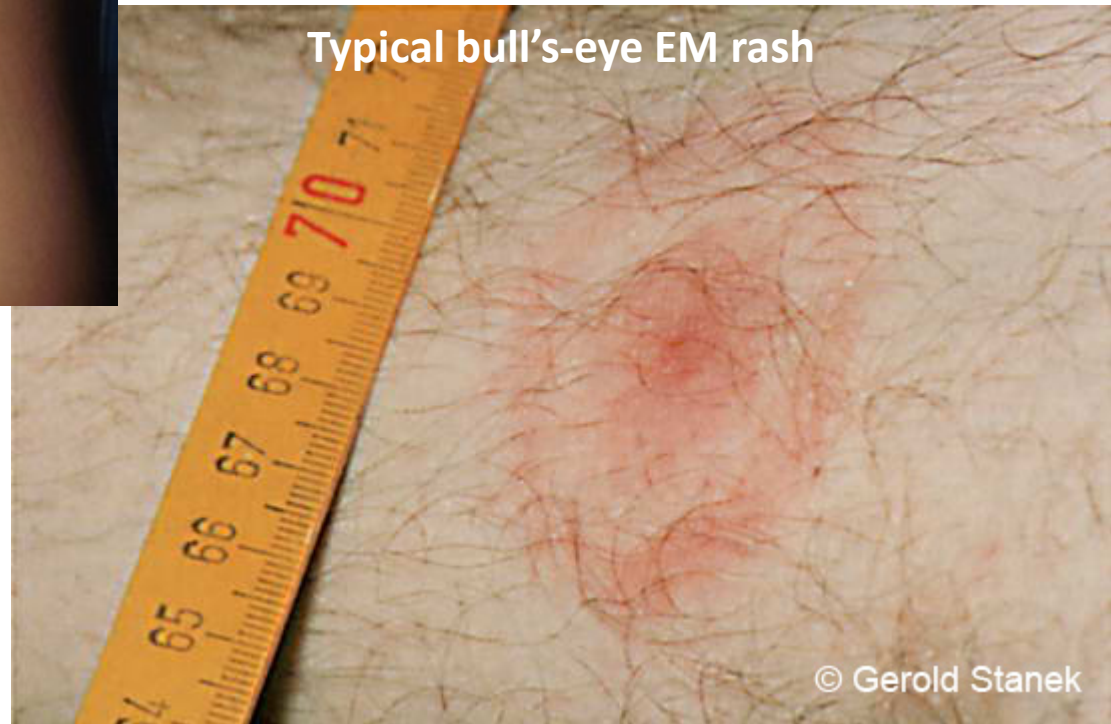
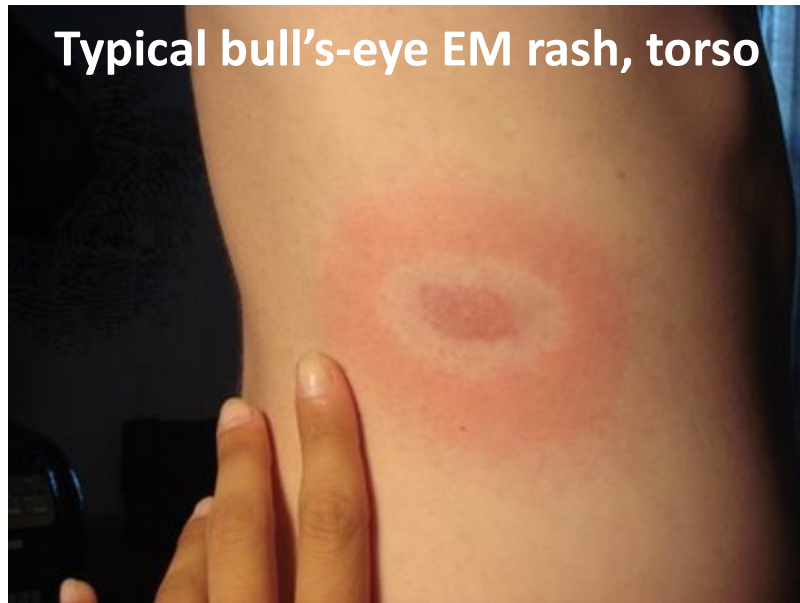




# Erythema migrans



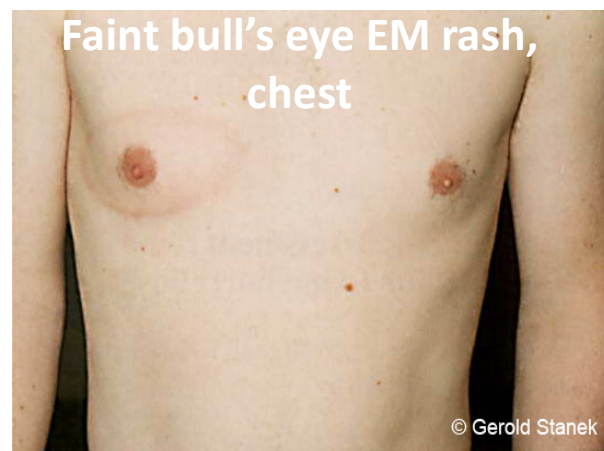
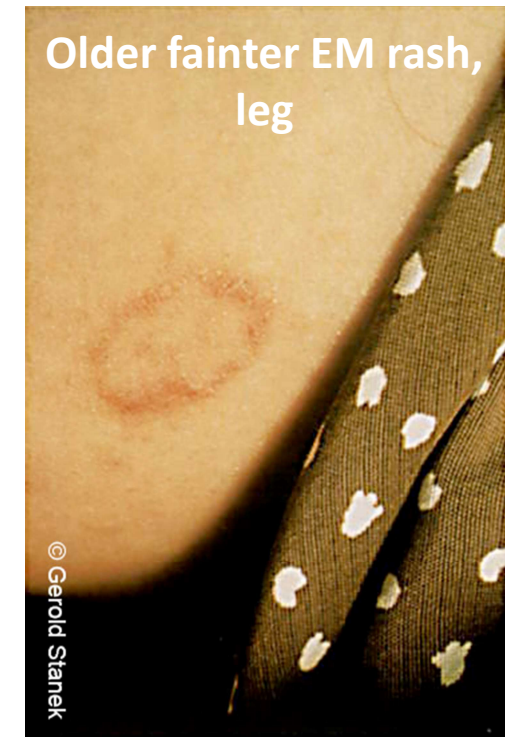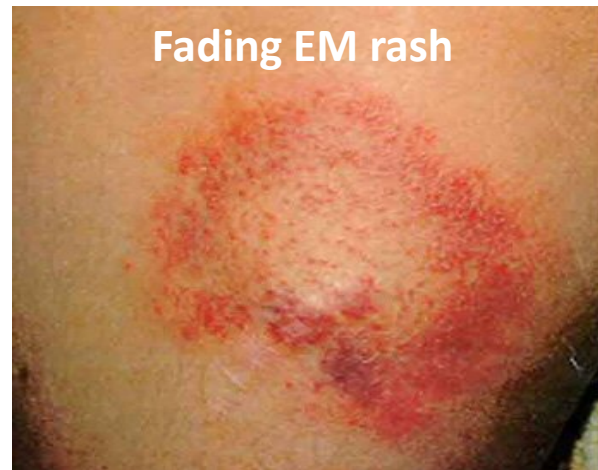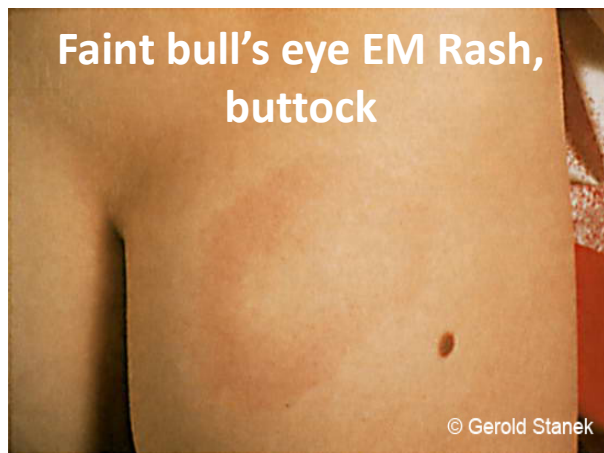## Erythema migrans - typical



© Gerold Stanek

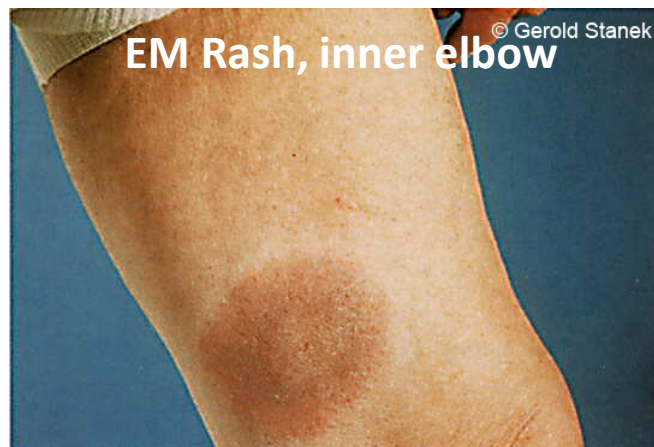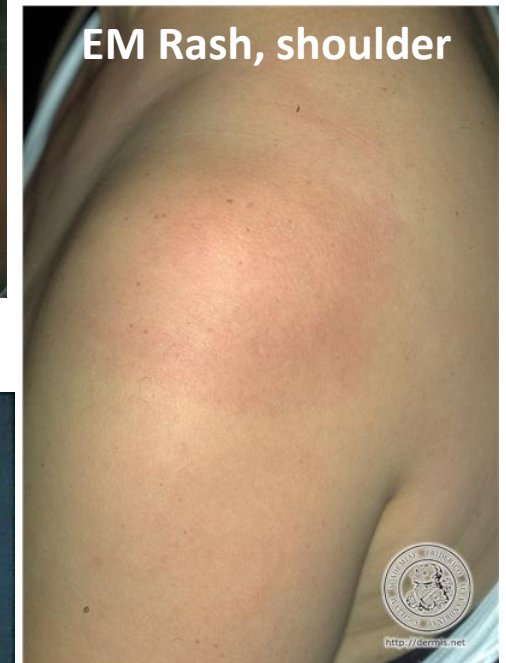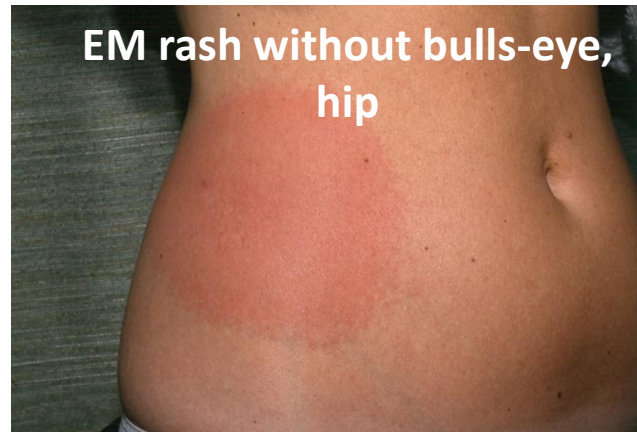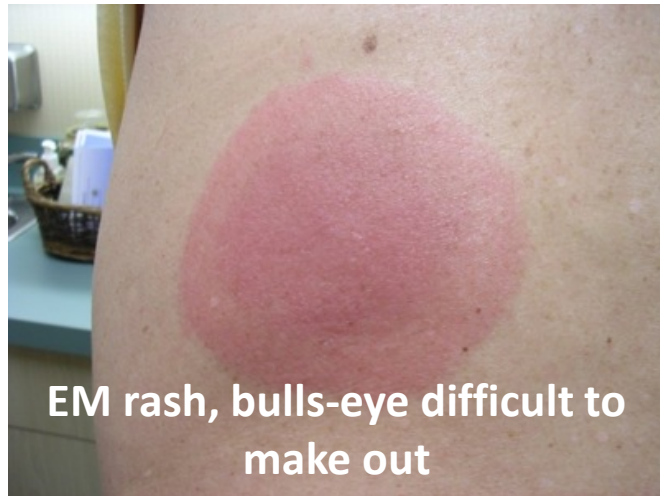


## Erythema migrans – faint or fading



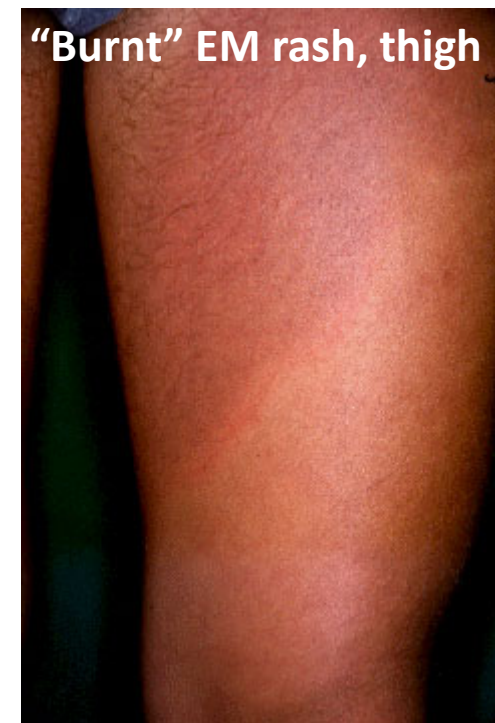
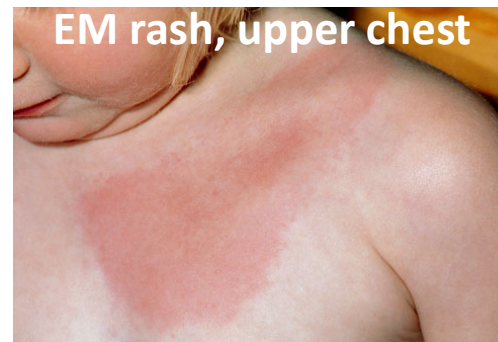
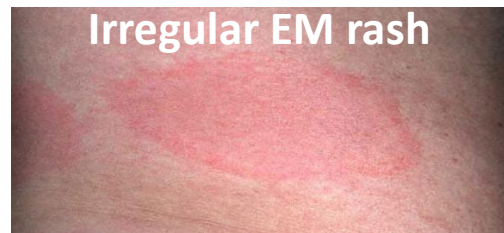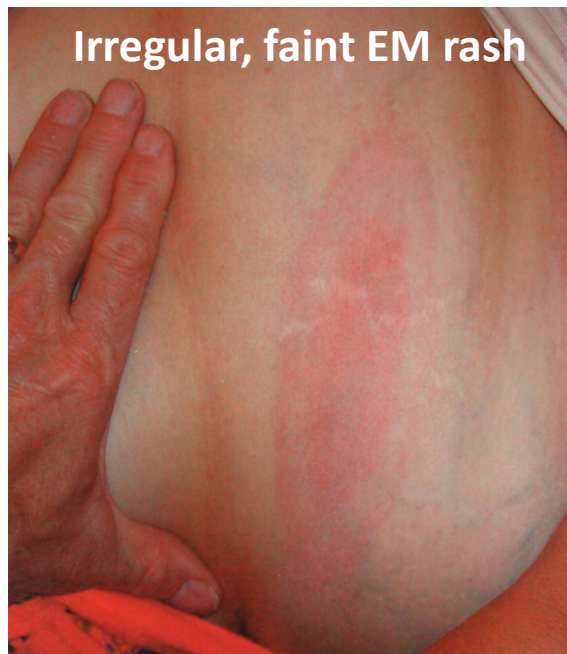## Erythema migrans – bulls eye absent or obscure



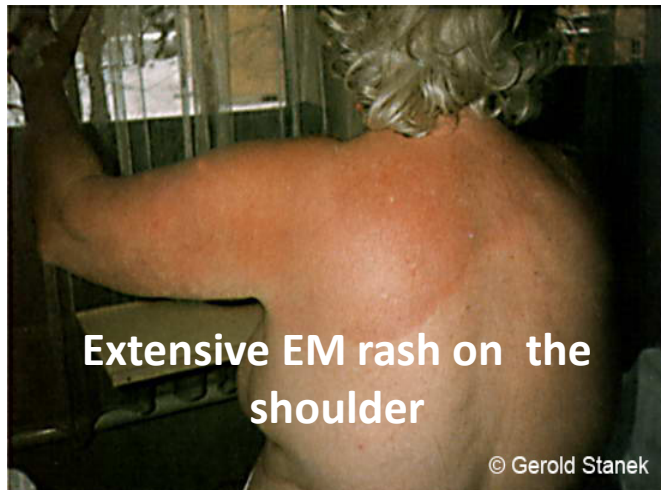

## Erythema migrans – irregular shape



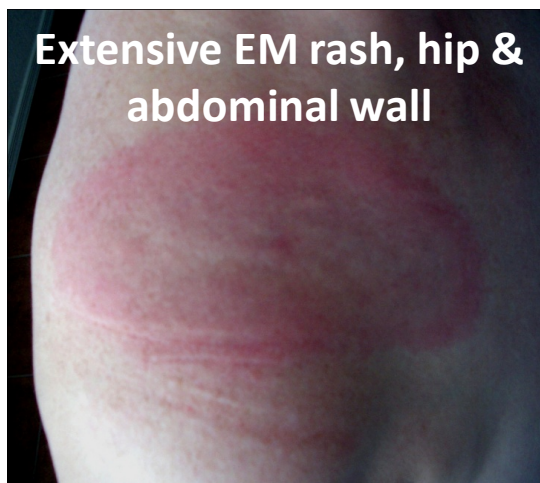

## Erythema migrans – extensive & multiple

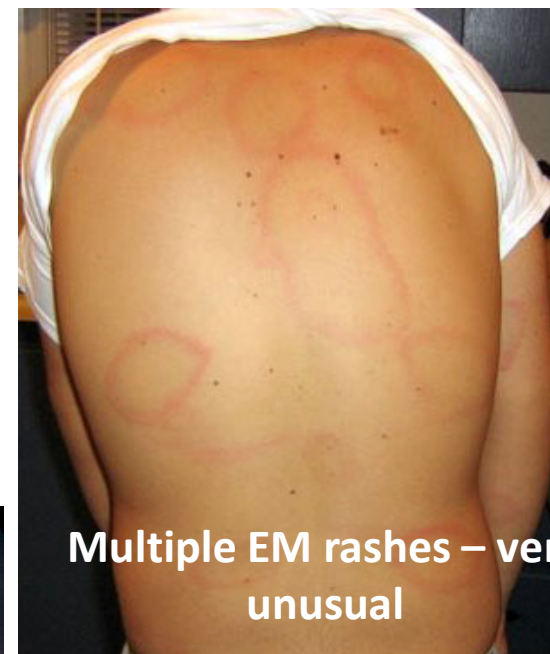

Extensive EM rash on the shoulder

© Gerold Stanek



Extensive EM rash, hip & abdominal wall



Multiple EM rashes – very unusual



## Erythema migrans – atypical rash

